

Breast Augmentation and Mastopexy Using a Pectoral Muscle Loop

André Auersvald · Luiz Augusto Auersvald

Received: 28 April 2010 / Accepted: 8 October 2010 / Published online: 3 November 2010
© Springer Science+Business Media, LLC and International Society of Aesthetic Plastic Surgery 2010

Abstract

Background Augmentation mastopexy has historically challenged the creativity of plastic surgeons. Recurrent breast ptosis is the main cause for revision after such a primary operation. Avoiding the need for reoperation and achieving long-term projection and upper pole fullness have been the main focus for the work of many authors. In this study, a new approach for a stable and lasting breast shape based on the use of the pectoral muscle was conceived.

Method Augmentation mastopexy was performed for patients with breast ptosis grades 2 and 3 according to Regnault's classification. With the proposed surgical technique, a loop of the pectoral muscle was used to keep the implant in a stable position. An inferior chest wall-based flap optimized coverage of the lower pole of the prosthesis.

Results From 2008 to 2009, 22 patients underwent augmentation mastopexy using the described technique. Of these 22 patients, 12 were indicated for grade 2 and 10 for grade 3 ptosis. The mean follow-up period was 11.9 months. A high level of satisfaction was observed. No major complications occurred.

Conclusions Augmentation mastopexy using a loop of the pectoral muscle to hold the implant is a new and effective way to obtain long-lasting projection and upper pole fullness.

Keywords Breast · Augmentation · Mastopexy · Breast augmentation and mastopexy · Pectoral muscle · Loop · Implant · Breast implant

Balancing shape, volume, and scar with a low recurrence rate is the main goal of clinicians considering lift and augmentation of the breast. Over decades of breast mastopexy and augmentation, surgeons have struggled with long-term and even early return of ptosis [1, 2]. The implant mass imposes a natural downward and unopposed force that generally induces a recurrence of the breast's descent. To avoid this, the authors developed a technique that keeps the prosthesis in a stable position using a loop of the pectoral muscle.

Materials and Methods

From March 2008 through September 2009, 22 patients underwent the authors' procedure. The inclusion criteria specified grade 2 or 3 breast ptosis according to Regnault's classification [3] in patients presenting for primary or revision breast augmentation. The exclusion criteria ruled out patients who had undergone previous submuscular breast augmentation. The patients were asked to grade their result on a scale of 1 (very poor), 2 (poor), 3 (satisfactory), 4 (very satisfactory), and 5 (excellent).

Surgical Technique

The authors have previously described their experience using a loop of the pectoral muscle to hold an inferior chest wall-based flap firmly in mammoplasty patients [4–6]. Based on this principle, a similar technique in augmentation mastopexy was developed. With this approach, vertical L-shaped or inverted T scars are used and chosen according to the degree of ptosis, quality of skin, and distance between the inframammary fold and the nipple-areolar complex (NAC).

A. Auersvald · L. A. Auersvald (✉)
Alameda Presidente Taunay, 1756, Curitiba,
PR 80430-000, Brazil
e-mail: luizauersvald@uol.com.br

Markings (Fig. 1)

Markings are done before the anesthetic procedure with the patient in a sitting position. The higher point of the NAC is marked, and the new point is established on an imaginary line above the original point. Importantly, the new point is slightly higher (~1 cm) than if the proposed technique were not used. The reason for this is that when the gland accommodates in natural healing, the NAC descends as well. The implant, on the other hand, tends to stay in the same position, held by the muscle. To match the stable implant with the descending gland, the NAC is therefore marked slightly higher.

Anesthesia

Epidural blockage associated with sedation is the authors' preferred anesthesia.

Inferior Chest Wall-Based Flap

Incision with a no. 15 blade scalpel and subsequent deepithelialization is performed. A horizontal plane is drawn approximately 3 to 6 cm below the incised areola. Perpendicular dissection through the gland is performed all the way to the pectoral muscle. The gland then is incised laterally, medially, and inferiorly through the rectus

abdominal fascia. The resulting flap is based on the chest wall and will be used later to cover the inferior pole of the implant. The upper portion of the breast is undermined to the second rib.

Pectoral Loop (Figs. 2, 3)

Just superior to the aforementioned flap, a loop of pectoral muscle is isolated. This loop, approximately 3 cm wide, follows the direction of the muscle fibers. It has two extremities: a lower extremity at about the fifth and sixth ribs around the sternal insertion and a higher extremity at about the second or third rib. The upward end point of the dissection is dependent on the size of the implant. Larger implants require higher dissections.

Implant Insertion (Figs. 4, 5, 6, 7, 8)

The implant is placed under the pectoral loop. Great care is taken in pulling the prosthesis downward using a Farabeuf retractor to hold the muscle. Pushing the implant upward jeopardizes the integrity of the muscle, especially at the sternal insertion. Approximately 40% of the implant should stay below the loop, and the remaining 60% should stay above the loop. To keep the muscle loop in a stable position, approximation to the retroareolar gland is performed

Fig. 1 Markings for augmentation mastopexy using the inverted T incision. Note that the patient's nipple-areolar complex (NAC) (A) is elevated to a point A', slightly higher than if the loop of muscle were not used to hold the implant

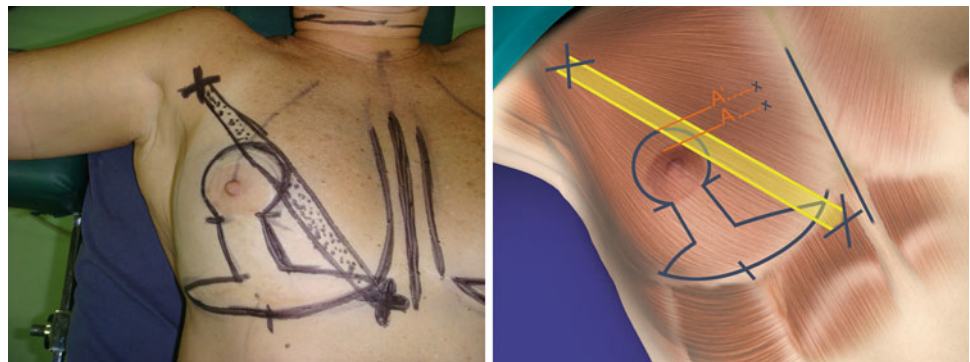

Fig. 2 After gland undermining, the loop is marked with methylene blue from its lower insertion around the sternum to the second or third rib

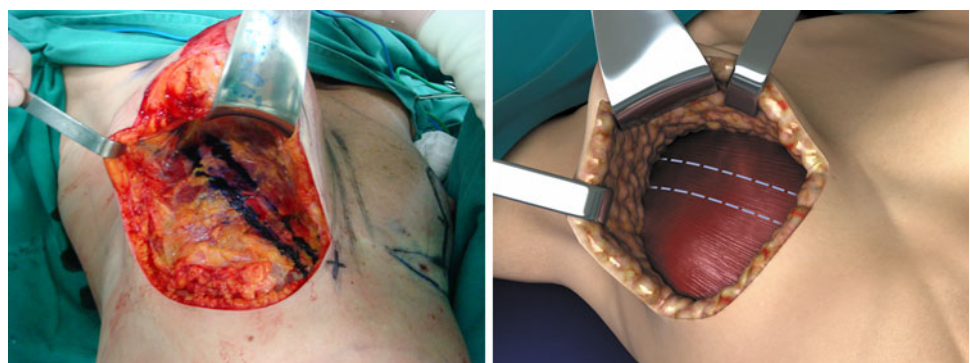


Fig. 3 Using electrocautery and a Farabeuf retractor, the loop is dissected

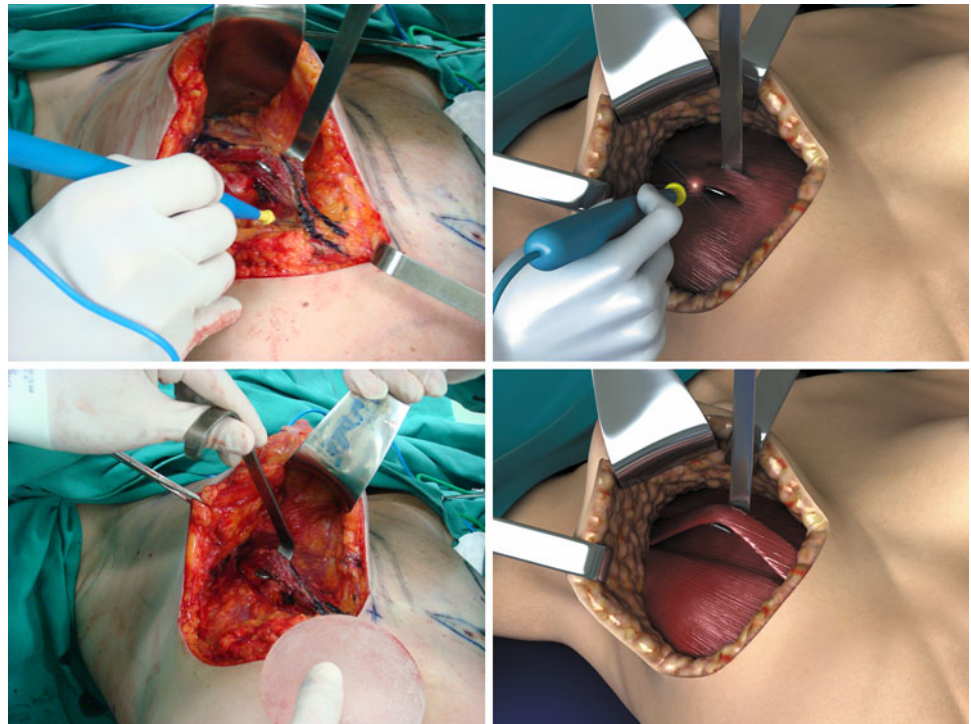


Fig. 4 The implant is placed in a downward direction. Care is taken not to disrupt the muscle fibers especially at the sternal insertion

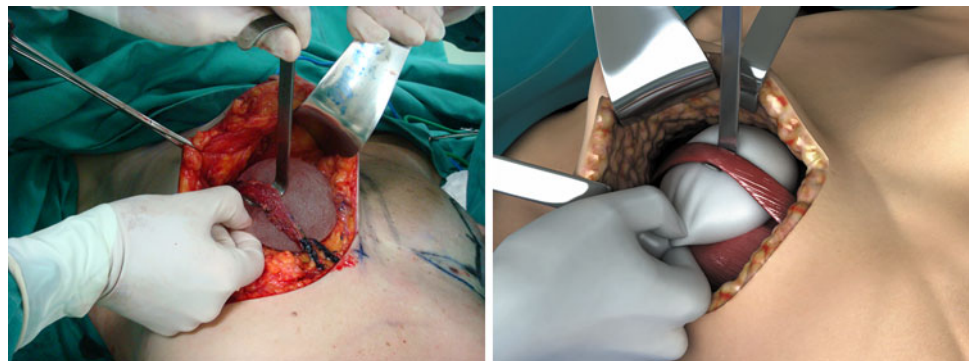


Fig. 5 At the end of the procedure, about 60% of the implant should remain above the loop and 40%, inferior to it

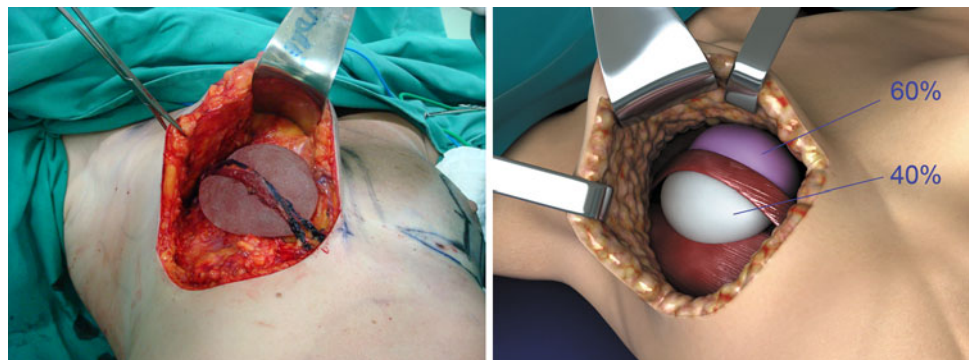


Fig. 6 The muscle loop is approximated to the retroareolar gland, which helps to keep the loop in a stable position

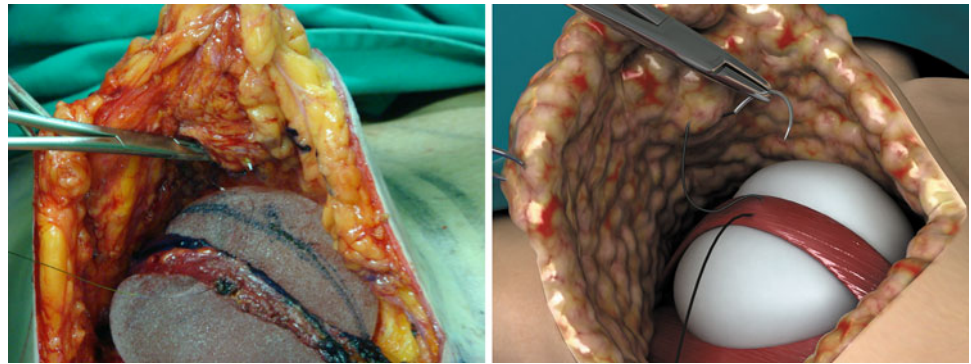


Fig. 7 The inferior pole of the implant is covered by the inferior flap previously dissected

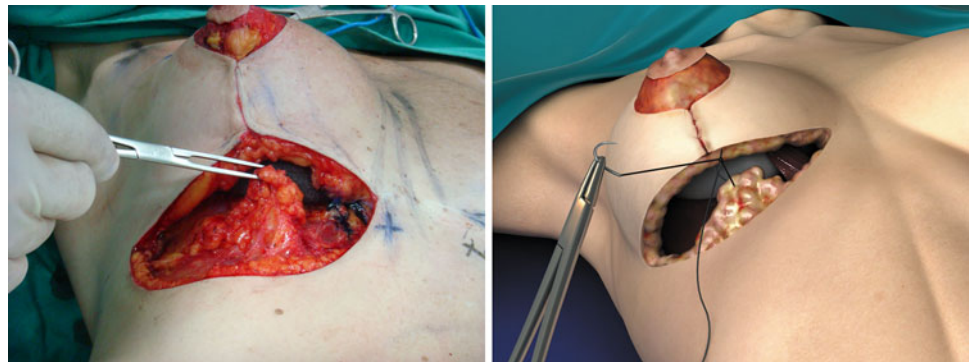
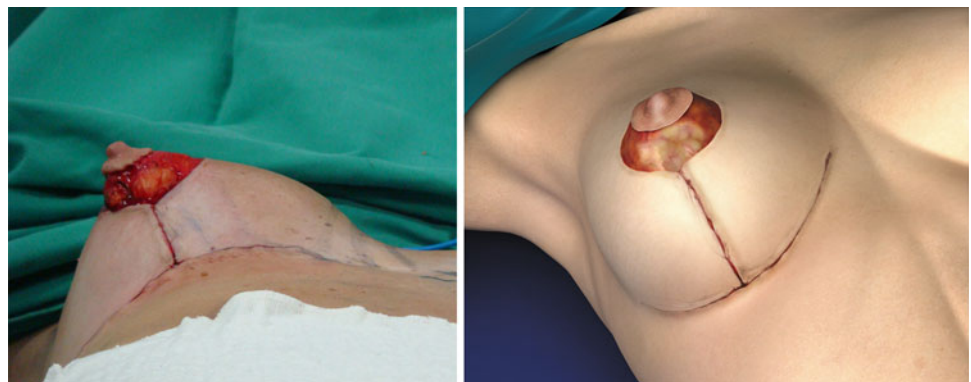


Fig. 8 Skin closure follows conventional technique



with a 3-0 poliglecaprone suture. The remaining gland approximation and skin suture follow conventional technique.

Results

A total of 22 patients underwent augmentation mastopexy. The descriptive information on these patients is presented in Table 1. The mean follow-up period was 11.9 months (range, 7–25 months), and the average age was 44 years (range, 17–74 years). Of the 22 patients, 12 (54%) had grade 2 ptosis, whereas 10 (46%) had grade 3 ptosis. Only three patients (13%) underwent secondary breast

augmentations. The majority of the patients ($n = 19$, 87%) underwent primary surgeries.

Most patients were satisfied with their results. No major complications occurred, and no cases of infection, implant malpositioning, or NAC necrosis were observed. Two patients (9%) had minor wound dehiscence and underwent scar revision. Figures 9 and 10 show two patients treated with the reported technique.

Discussion

Augmentation mastopexy is one of the most challenging aesthetic procedures [1, 2, 7–10]. Addressing hypomastia

Table 1 Summary of patient descriptive data

Patient no.	Age (years)	Ptois grade	Implant size (ml)	Implant shape	Follow-up months	Incision pattern	Patient satisfaction
1	32	2	285	Conical; polyurethane	25	Inverted T	3
2	45	3	155	Conical; polyurethane	22	Inverted T	3
3	74	3	190	Round; high profile	20	Inverted T	4
4	41	2	190	Round; high profile	18	Inverted T	3
5	30	2	280	Round; high profile	15	Inverted T	2
6	36	3	230	Round; high profile	14	Inverted T	3
7	38	3	280	Round; high profile	13	Inverted T	4
8	17	2	160	Round; high profile	12	L-shaped	3
9	47	2	160	Round; high profile	11	Inverted T	4
10	48	2	160	Round; high profile	11	Vertical	3
11	60	2	160	Round; high profile	10	Inverted T	4
12	44	3	310	Round; high profile	10	Inverted T	4
13	35	2	160	Round; high profile	9	Inverted T	5
14	32	2	160	Round; high profile	9	Inverted T	4
15	42	2	160	Round; high profile	9	Inverted T	4
16	52	3	190	Round; high profile	9	Inverted T	4
17	71	2	160	Round; high profile	8	Vertical	5
18	43	3	230	Round; high profile	8	Inverted T	4
19	62	3	280	Round; high profile	8	Inverted T	4
20	26	3	280	Round; high profile	7	Inverted T	5
21	46	2	285	Conical; polyurethane	7	Inverted T	4
22	49	3	230	Round; high profile	7	Inverted T	4

and breast ptosis in a single procedure demands thorough discussion of the patient's expectations, adequate planning, and great care in executing the operation.

The relatively high revision rates previously described (14%) are a strong reason for a careful approach with a candidate for this surgery [1]. Patients should be informed concerning the limitations of the procedure, the resulting scars, and most importantly, the possible complications and causes for eventual revisions. Nipple malpositioning, poor scarring, capsular contracture, and recurrent ptosis are, in ascending order, among the most common reports that result in a new operation [1]. In the authors' personal experience, the latter is also the most frequent cause of dissatisfaction. To prevent the early return of breast ptosis, the current technique was developed.

The starting point for the idea of placing the implant under a loop of pectoral muscle was the authors' experience with this approach in reduction mammoplasty and mastopexy [4]. With this technique, the muscle helps to keep the gland in a stable position, with little lateral tilting even in the supine position. By analogy, we hypothesized that the use of the loop would have the same effect on the implant. The authors also were encouraged by the results presented with the use of a pocket of pectoral muscle to treat breast ptosis [11].

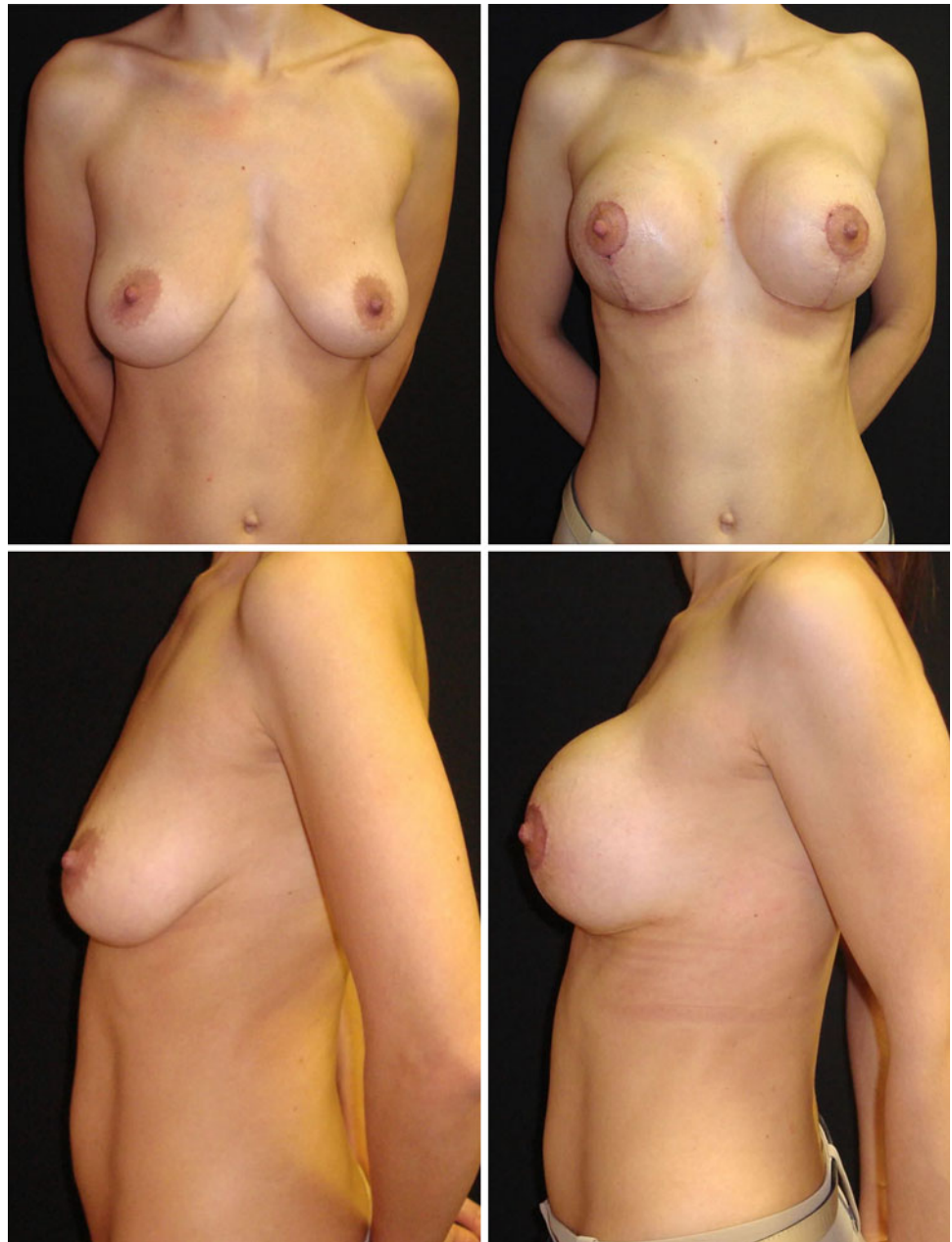
When planning the procedure, the surgeon should be careful in marking the new NAC position. The implant usually dislocates the center of the breast mass slightly higher than with a mastopexy or reduction mammoplasty [1]. With the proposed technique, this should be considered with even more caution because the implant is held firmly in a definite position.

Although L-shaped and vertical incisions were used in a few cases, most of the patients had inverted T incisions. The short scars (L-shaped and vertical) are best indicated for patients with grade 2 ptosis and firm skin. In the authors' experience, the inverted T favors breast projection and the treatment of excess skin. It also facilitates the undermining and the muscle loop dissection. Therefore, this approach is best indicated for grade 2 ptosis with thin skin and for grade 3 regardless of the skin quality. Given the relative inadequacy in treating the excess skin as well as the difficulty dissecting the muscle, periareolar incision was not indicated.

One positive aspect of this technique is the predictability of the implant position. This is especially important in the treatment of patients with very ptotic breasts, such as after massive weight loss.

The effect of the muscle string on the implant is another issue that had to be thought through in the process of

Fig. 9 Surgery using the proposed technique. Frontal and lateral views (preoperative, *left*; postoperative, *right*) are shown



conceiving this technique. Two reasons led us to think that this operative approach would not affect implant integrity. First, augmentation mastopexies performed without the loop already impose localized pressures over the implants given the often strong pulling of gland and skin necessary to achieve the final breast shape. Second, the muscle, when well dissected and freed, leaves enough space to accommodate the implant. Figure 11 shows a magnetic resonance imaging (MRI) scan of a patient 12 months after the reported procedure. Fortunately, no major complications were found. Two patients experienced a small dehiscence and underwent scar revision.

In the current study, during an average follow-up period of 11.9 months, no patient required reoperation for recurrent ptosis. Interestingly, at this writing, upper pole fullness has persisted, and breast projection has been adequate.

Conclusions

This report presents a new approach for augmentation mastopexy using a loop of the pectoral muscle to hold the implant. The technique was effective in obtaining

Fig. 10 Surgery with the proposed technique. Frontal and lateral views (preoperative, *left*; 20th postoperative month, *right*) are shown

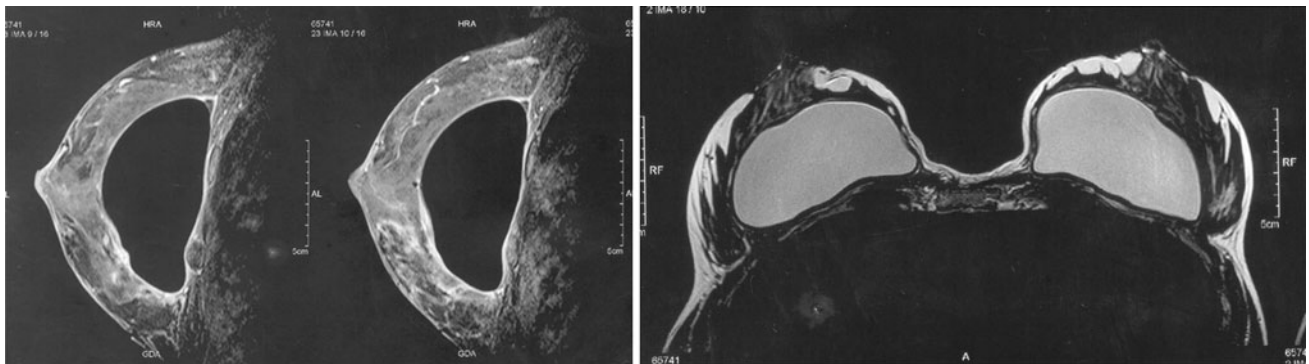
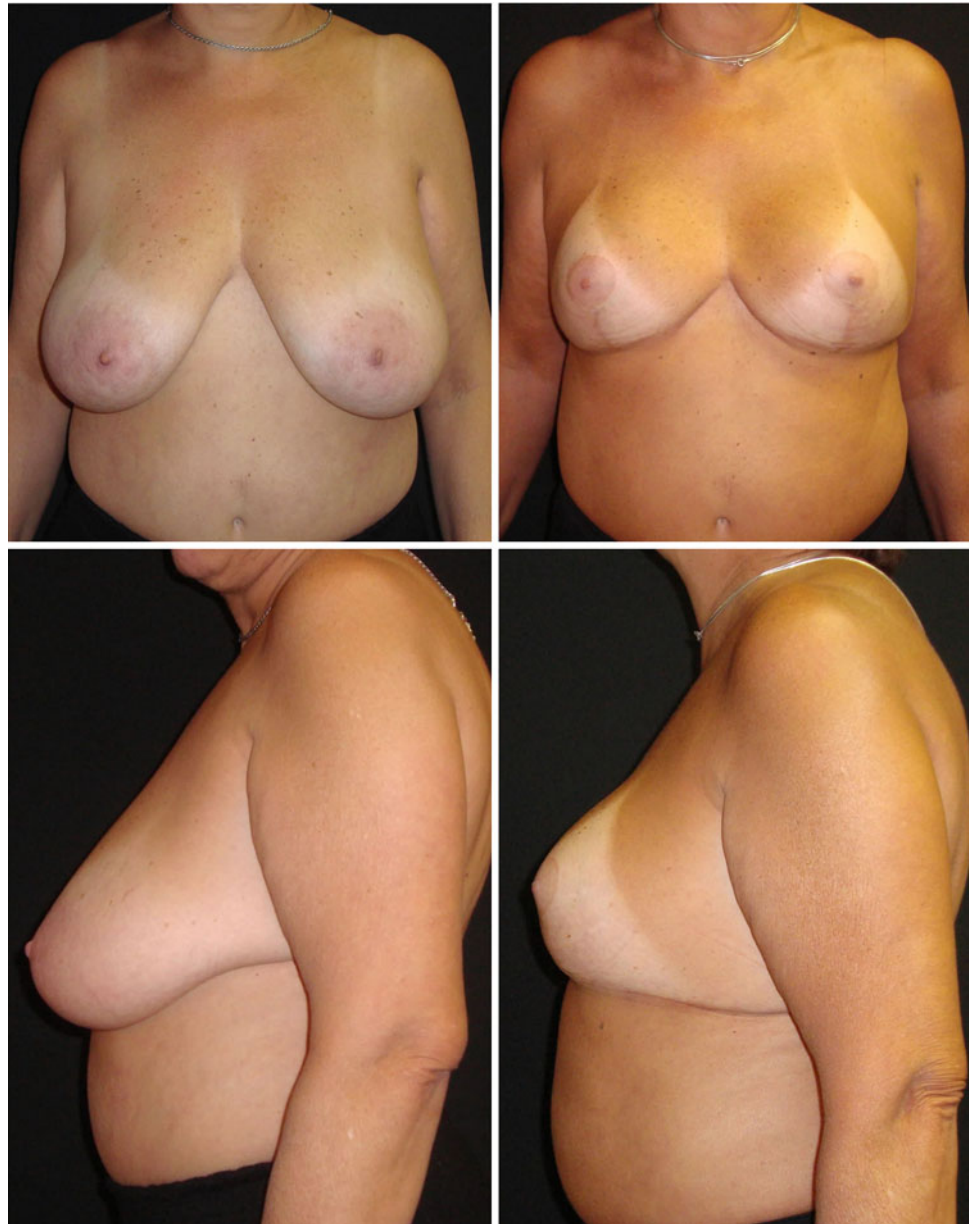

Fig. 11 Magnetic resonance imaging (MRI) scan at postoperative month 10 showing integrity of the implant and the pectoral muscle loop

long-lasting projection and upper pole fullness. No patient required reoperation for recurrent ptosis.

Although this approach is not the only answer for the complex issue of mastopexy and augmentation, it may be another useful tool for plastic surgeons to reach more enduring results.

Conflict of interest None.

References

1. Spear SL, Boehmler JH IV, Clemens MW (2006) Augmentation/mastopexy: a 3-year review of a single surgeon's practice. *Plast Reconstr Surg* 118(7Suppl):136S
2. Stevens WG, Freeman ME, Stoker DA, Quardt SM, Cohen R, Hirsch EM (2007) One-stage mastopexy with breast augmentation: a review of 321 patients. *Plast Reconstr Surg* 120:1674
3. Regnault P (1976) Breast ptosis: definition and treatment. *Clin Plast Surg* 3:193
4. Graf RM, Auersvald A, Bernardes A, Biggs TM (2000) Reduction mammoplasty and mastopexy with shorter scar and better shape. *Aesthetic Plast Surg* 20:99
5. Daniel M (1995) Mammoplasty with pectoral muscle flap. Presented at the 64th American annual scientific meeting, Montreal. pp 193–195
6. Ribeiro L (1975) A new technique for reduction mammoplasty. *Plast Reconstr Surg* 55:330
7. Spear SL, Venturi ML (2006) Augmentation with periareolar mastopexy. In: Spear SL (ed) *Surgery of the breast: principles and art*, vol 2, 2nd edn. Lippincott Williams & Wilkins, Philadelphia, pp 1393–1402
8. Elliot LF (2002) Circumareolar mastopexy with augmentation. *Clin Plast Surg* 29:337
9. Gruber R, Denkler K, Hvistendahl Y (2006) Extended crescent mastopexy with augmentation. *Aesthetic Plast Surg* 30:269
10. Auersvald A, Auersvald LA (2006) Extended crescent mastopexy with augmentation. *Aesthetic Plast Surg* 30:275
11. Daniel MJB (2005) Inclusão de prótese de mama em duplo espaço (inclusion of the breast prosthesis in double space). *Rev Soc Bras Cir Plast* 20:82